

Aquilion ONE Clinical Evidence: Pediatric

[CT Angiography of Neonates and Infants: Comparison of Radiation Dose and Image Quality of Target Mode Prospectively ECG-Gated 320-MDCT and Ungated Helical 64-MDCT](#)

Siddharth P. Jadhav, Farahnaz Golriz, Lamy A. Atweh, Wei Zhang, Rajesh Krishnamurthy

AJR 2015; 204:W184–W191

- Target mode prospectively ECG-gated volumetric scanning with iterative reconstruction performed with a 320-MDCT scanner has several benefits including low radiation dose, improved image quality, high diagnostic accuracy, and ability to perform free-breathing studies

[Diagnostic Performance and Dose Comparison of Filtered Back Projection and Adaptive Iterative Dose Reduction Three dimensional CT Enterography in Children and Young Adults](#)

Daniel B. Wallihan, Daniel J. Podberesky, John Sullivan, Lee A. Denson, Bin Zhang, Shelia R. Salisbury, Alexander J. Towbin

Radiology 2015, Epub ahead of print

- Reduced-dose CT enterography with AIDR 3D allowed substantial dose reduction compared with that used with FBP CT enterographic examinations, while maintaining a high diagnostic performance

[Optimizing Image Quality for Pediatric Torso Computed Tomography: The Use of Advanced Iterative Reconstruction and Wide-Detector Scanning Techniques](#)

Robert F. Buchmann, S. Bruce Greenberg

J Comput Assist Tomogr, 2014, ePub ahead of print

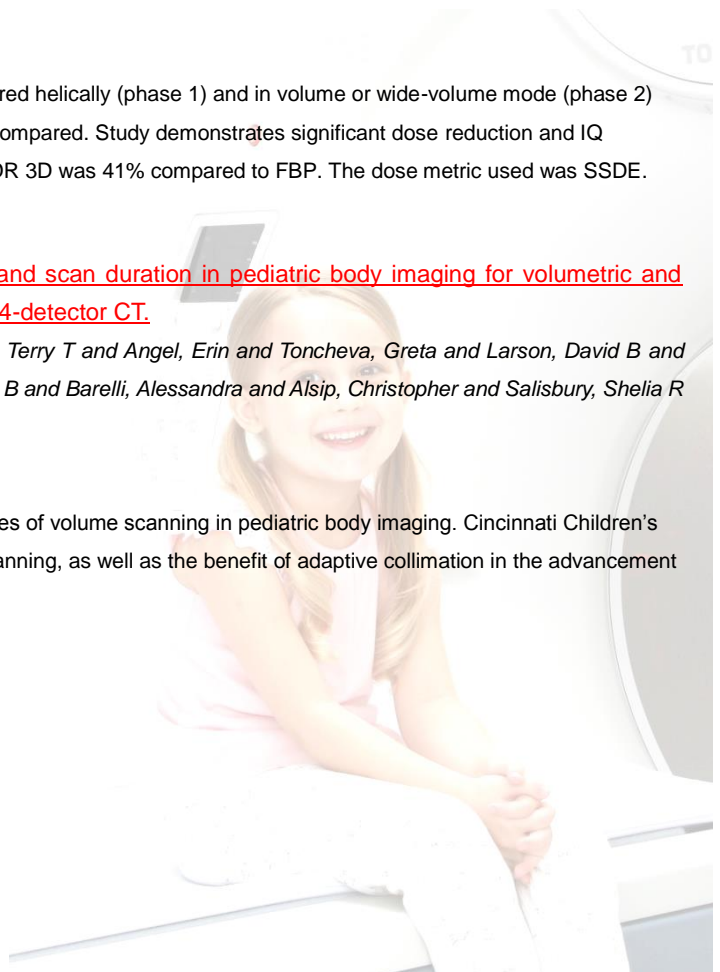
- A study comparing clinical pediatric torso scans acquired helically (phase 1) and in volume or wide-volume mode (phase 2) with and without AIDR 3D. Dose and IQ (noise) was compared. Study demonstrates significant dose reduction and IQ improvement using AIDR 3D. Dose reduction with AIDR 3D was 41% compared to FBP. The dose metric used was SSDE.

[Comparison of radiation dose estimates, image noise, and scan duration in pediatric body imaging for volumetric and helical modes on 320-detector CT and helical mode on 64-detector CT.](#)

Johnston, Jennifer H and Podberesky, Daniel J and Yoshizumi, Terry T and Angel, Erin and Toncheva, Greta and Larson, David B and Egelhoff, John C and Anderson-Evans, Colin and Nguyen, Giao B and Barelli, Alessandra and Alsip, Christopher and Salisbury, Shelia R and Frush, Donald P

Pediatric Radiology, 2013, epub

- An excellent technical paper to highlight the advantages of volume scanning in pediatric body imaging. Cincinnati Children's hospital has highlighted the advantages of volume scanning, as well as the benefit of adaptive collimation in the advancement of low dose scans as technology advances.



[Comparison of Radiation Dose Estimates and Scan Performance in Pediatric High-Resolution Thoracic CT for Volumetric 320-Detector Row, Helical 64-Detector Row, and Noncontiguous Axial Scan Acquisitions.](#)

Podberesky, Daniel J and Angel, Erin and Yoshizumi, Terry T and Toncheva, Greta and Salisbury, Shelia R and Brody, Alan S and Alsip, Christopher and Barelli, Alessandra and Egelhoff, John C and Anderson-Evans, Colin and Nguyen, Giao B and Dow, David and Frush, Donald P

Academic Radiology, 2013, epub

- An excellent technical paper to highlight the advantages of volume scanning in HRCT of the chest. Cincinnati Children's hospital has highlighted the advantages of volume scanning, as well as the benefit of adaptive collimation in the advancement of low dose scans as technology advances.

[Case Report Volumetric Computed Tomography Angiography in the Evaluation of Mediastinal Fluid Collections following Congenital Cardiac Surgery](#)

Roest, Arno A W and Roelofs, Joost and Hazekamp, Mark G and Rijlaarsdam, Marry E B and Geleijns, Jacob and Kroft, Lucia J M

Case Reports in Pediatrics

- One rotation scanning in a pediatric setting provides so much useful knowledge, especially in patients with congenital heart defects. The post-surgical anatomy and physiology of these patients can be imaged easily and thoroughly with volumetric imaging.

[Radiation Dose Estimation for Prospective and Retrospective ECG-Gated Cardiac CT Angiography in Infants and Small Children Using a 320-MDCT Volume Scanner.](#)

Podberesky, Daniel J and Angel, Erin and Yoshizumi, Terry T and Toncheva, Greta and Salisbury, Shelia R and Alsip, Christopher and Barelli, Alessandra and Egelhoff, John C and Anderson-Evans, Colin and Nguyen, Giao B and Dow, David and Frush, Donald P

AJR, 2012, 199(5):1129-35

- Effective Doses for 320-MDCT volumetrically acquired ECG-gated pediatric cardiac CTA are lower than those published for conventional 16- and 64-MDCT scanners

[Initial experience on the application of 320-row CT angiography with low-dose prospective ECG-triggered in children with congenital heart disease.](#)

Zhang T, Wang W, Luo Z, Wang D, Bai J, Han D, Shen B.

Int J Cardiovasc Imaging. 2011 Dec 28. [Epub ahead of print]

- The study demonstrated that excellent diagnostic accuracy could be obtained by the use of Aquilion ONE prospective ECG gated CT angiography with very low radiation dose on children with congenital heart disease. The diagnostic results were compared to surgical or cardiac angiography results to establish the estimation of diagnostic accuracy. It was shown that CTA with Aquilion ONE could be achieved with very low effective dose (<1mSv) for this group of very young pediatric patients.

[Experience with volumetric \(320 rows\) pediatric CT](#)

Sorantin, E. and Riccabona, M. and Stucklschweiger, G. and Guss, H. and Fötter, R.

European Journal of Radiology, 2012, Epub ahead of print

- This paper describes the dose and time advantages of volume scanning in scanning small children predominantly in terms of the chest, spine and extremities. While the paper mentions a reduced dose for volume compared to helical acquisitions. The paper is be useful in demonstrating the clinical utility of the 320-row unit with a relatively large number of imaged clinical examples

CT in children – dose protection and general considerations when planning a CT in a child

Sorantin, E. and Weissensteiner, S. and Hasenburger, G. and Riccabona, M.

European Journal of Radiology, 2012, Epub ahead of print

- Good tips for reducing dose in pediatrics with a nice mention of the benefits of wide coverage. Not a strong marketing paper but useful for customers asking for advice on lowering pediatric doses.

Perfusion CT in childhood stroke-Initial observations and review of the literature.

Zebedin, D and Sorantin, E and Riccabona, M

European Journal of Radiology, 2012, Epub ahead of print

- This paper describes the experience of Graz in acute stroke imaging of 10 pediatric patients over two years. Image quality was rated as excellent to good. Advocates Aquilion ONE as an accurate imaging test in imaging children with stroke like symptoms. In addition, provides high quality 4D DSA. More widely available than MRI, with less need for sedation.

Use of 320-Detector Computed Tomographic Angiography for Infants and Young Children with Congenital Heart Disease.

Al-Mousily, Faris and Shifrin, Roger Y and Fricker, Frederick J and Feranec, Nicholas and Quinn, Nancy S and Chandran, Arun

Pediatric Cardiology, 2011 Jan, 32

- This paper focuses on congenital heart disease. Shows low dose cardiac CT imaging using the Aquilion ONE for non-gated and prospectively gated exams.

Scan time and patient dose for thoracic imaging in neonates and small children using axial volumetric 320-detector row CT compared to helical 64-, 32-, and 16- detector row CT acquisitions.

Kroft Lucia J M, Roelofs Joost J H, Geleijns Jacob

Pediatric Radiology, 2010 Mar, 40

- A phantom study comparing dose and scan time for various scan modes. Shows that volumetric scanning significantly reduces scan time and can reduce radiation dose when compared to 16 and 64 slice helical scan modes.